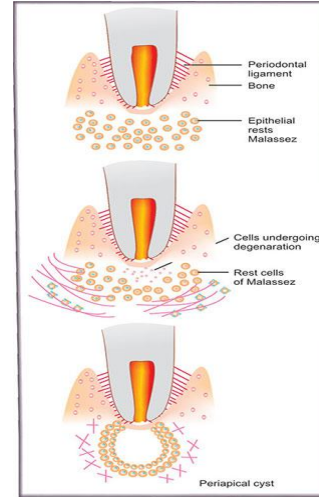


# **CYST DEVELOPMENT – RADICULAR CYST**

---

Caries, trauma, periodontal disease

## Radicular cyst



Pulpal necrosis( death of pulp tissue)

Necrotic debris is inflammatory stimulus

Periapical inflammation

Periapical granuloma

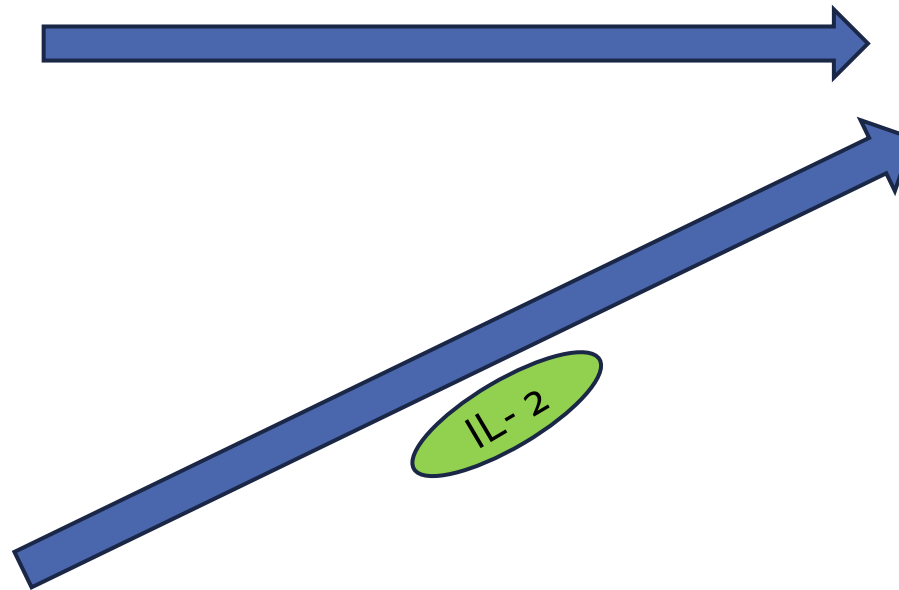
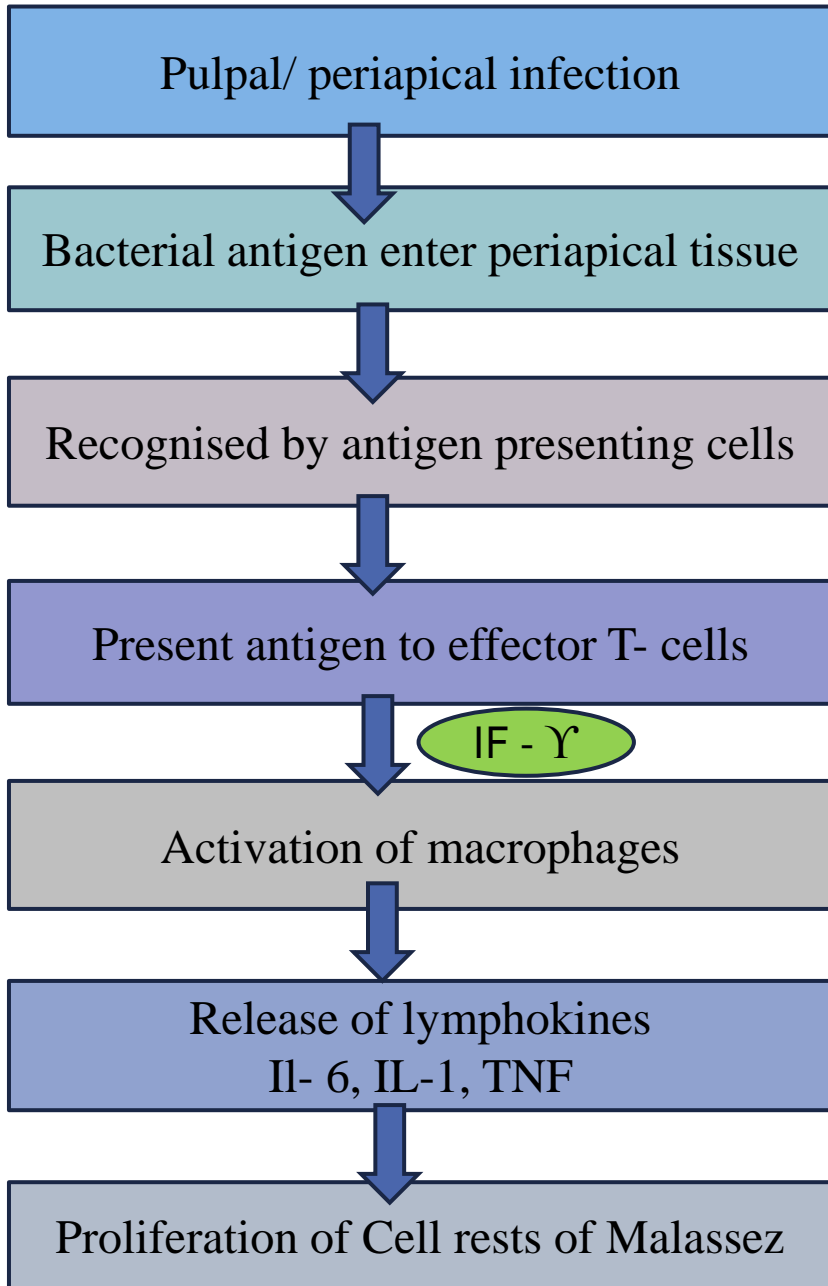
Radicular/ periapical cyst

Formation of cyst in the centre of granuloma

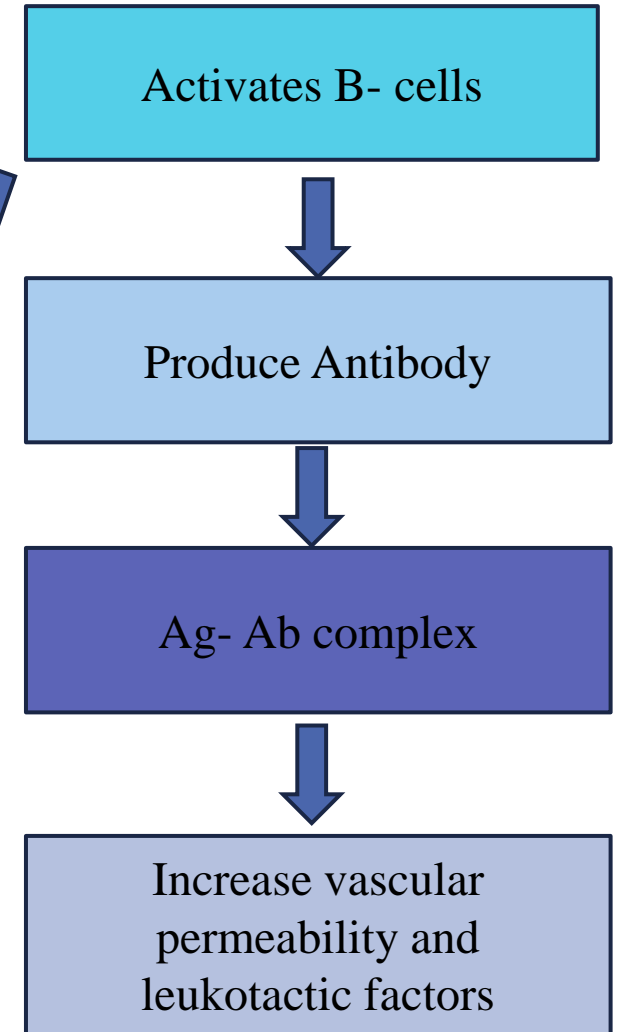
Inner mass of cells deprived of nourishment

Undergo liquefaction necrosis

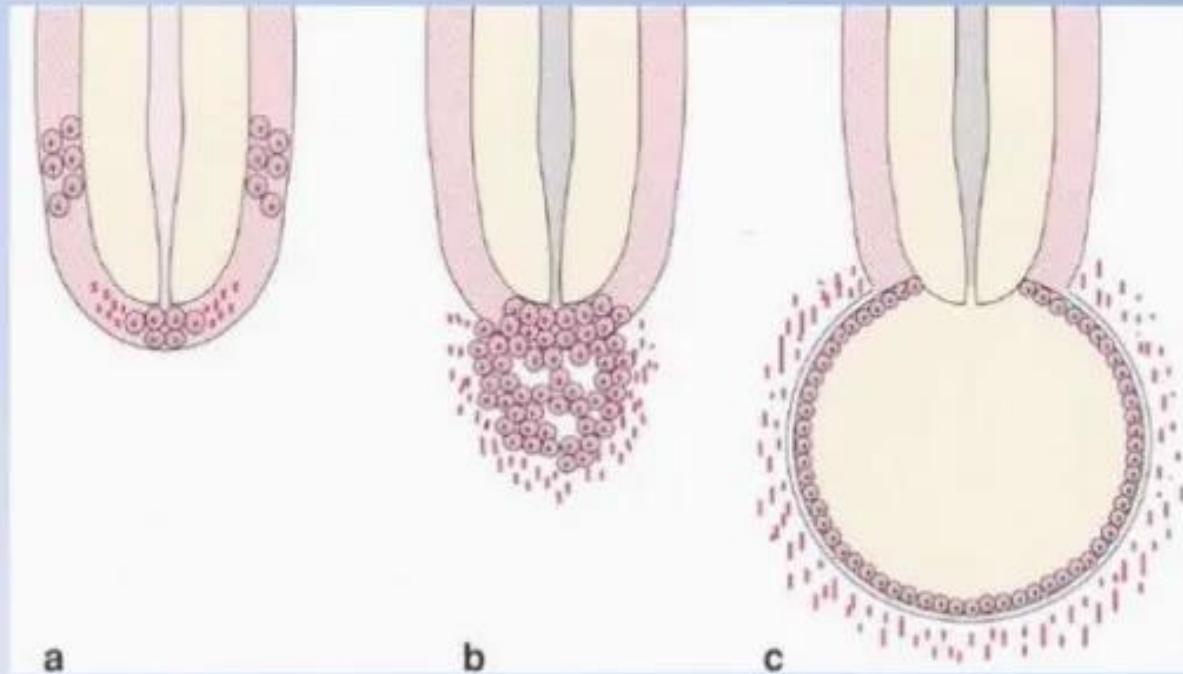
Proliferation of cell rests of Malassez to form large mass of cells



**Radicular cyst**



## ***Radicular cyst / pathogenesis***



***a Initiation***

***b Cyst formation***

***c Cyst enlargement***