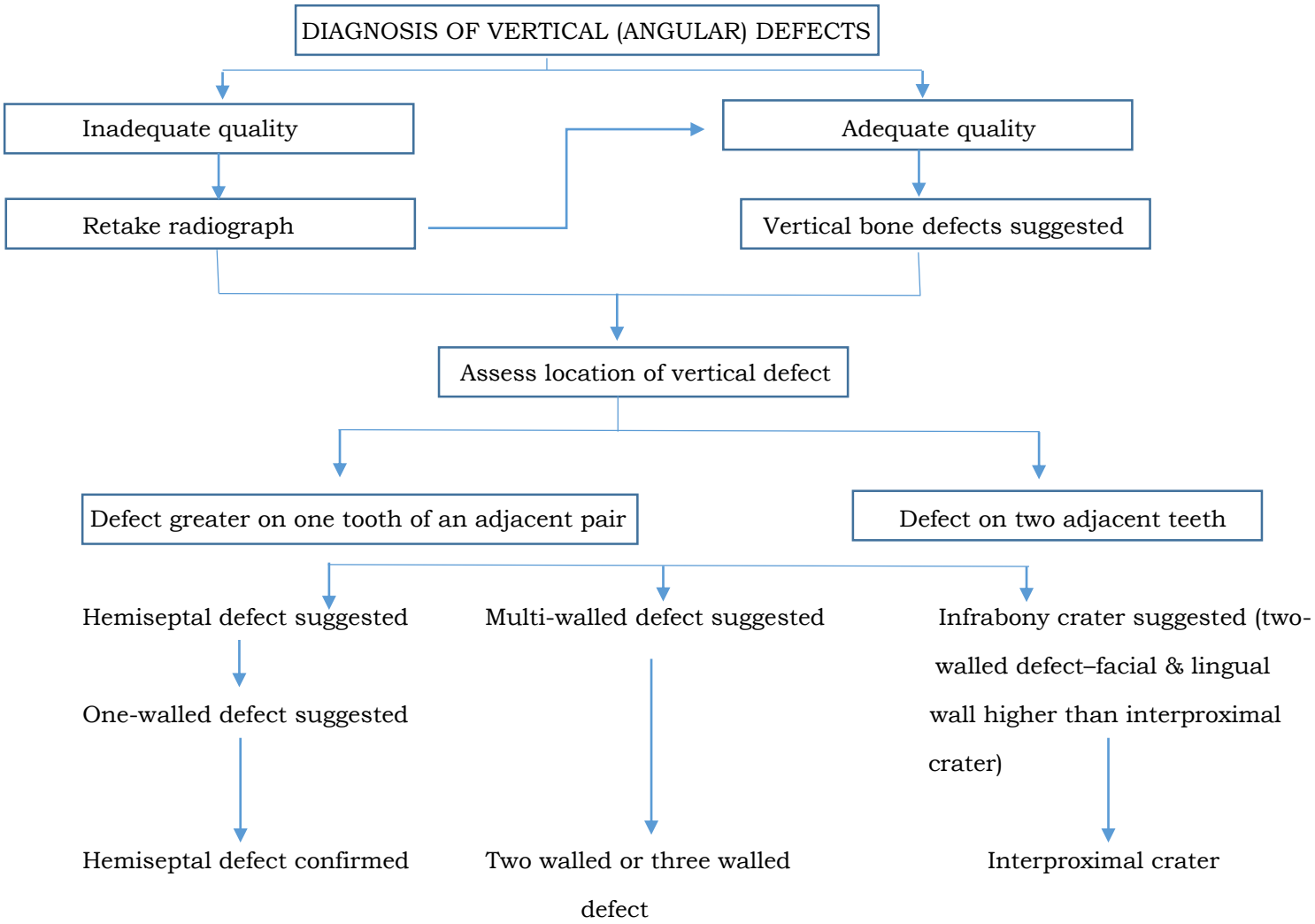
DIAGNOSIS OF VERTICAL (ANGULAR) DEFECTS
Inadequate quality
Adequate quality
Retake radiograph
Vertical bone defects suggested
Assess location of vertical defect
Defect greater on one tooth of an adjacent pair
Defect on two adjacent teeth
Hemiseptal defect suggested
Multi-walled defect suggested
Infrabony crater suggested (two-walled defect–facial & lingual wall higher than interproximal crater)
One-walled defect suggested
Hemiseptal defect confirmed
Two walled or three walled defect
Interproximal crater