

CLASS III MALOCCLUSION

Features of Class III malocclusion

Prognathic mandible

Retrognathic maxilla

A combination of the above

Changes in Inclination of Incisors

Functional shift in some cases

Etiology

Inherited

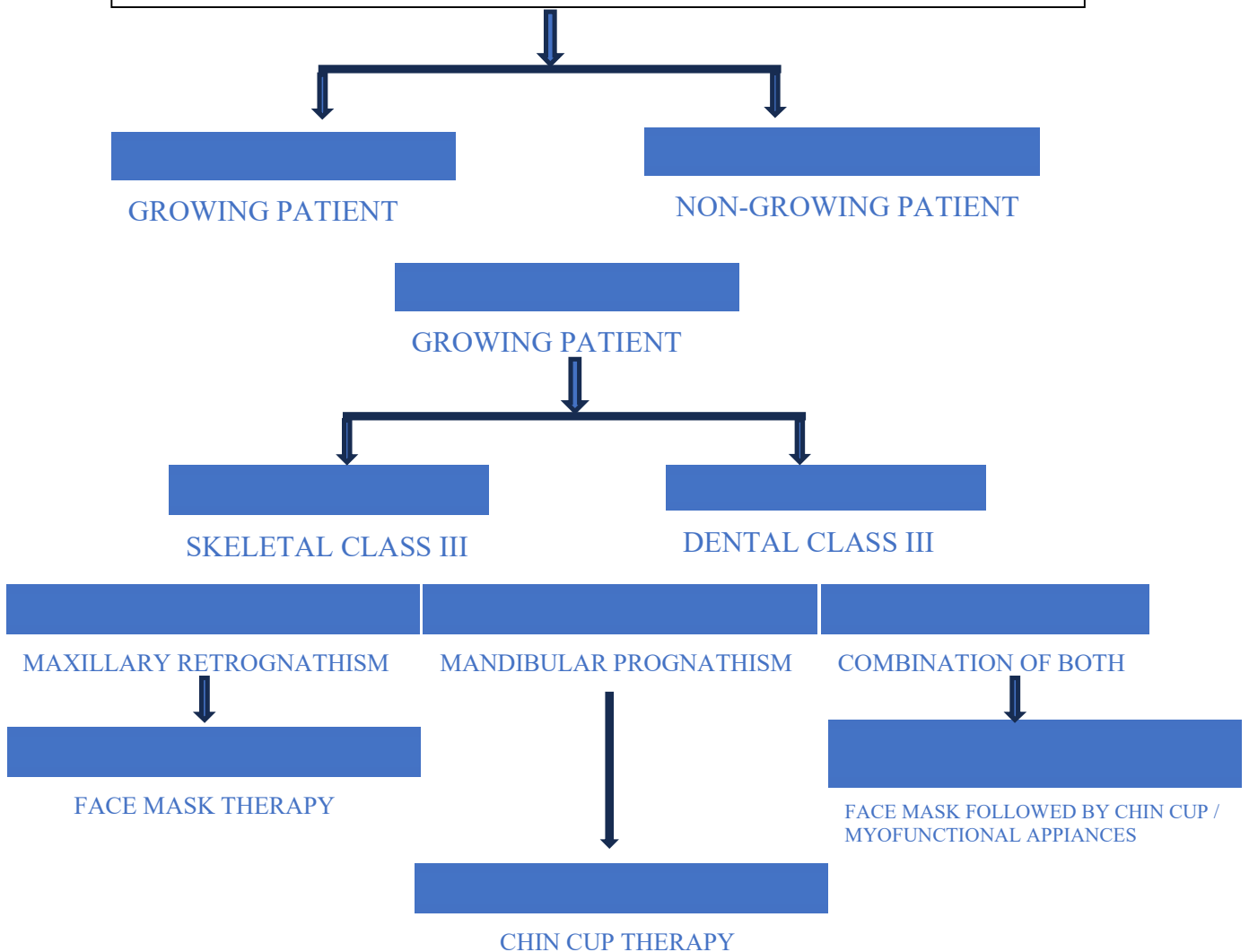
Environmental factors

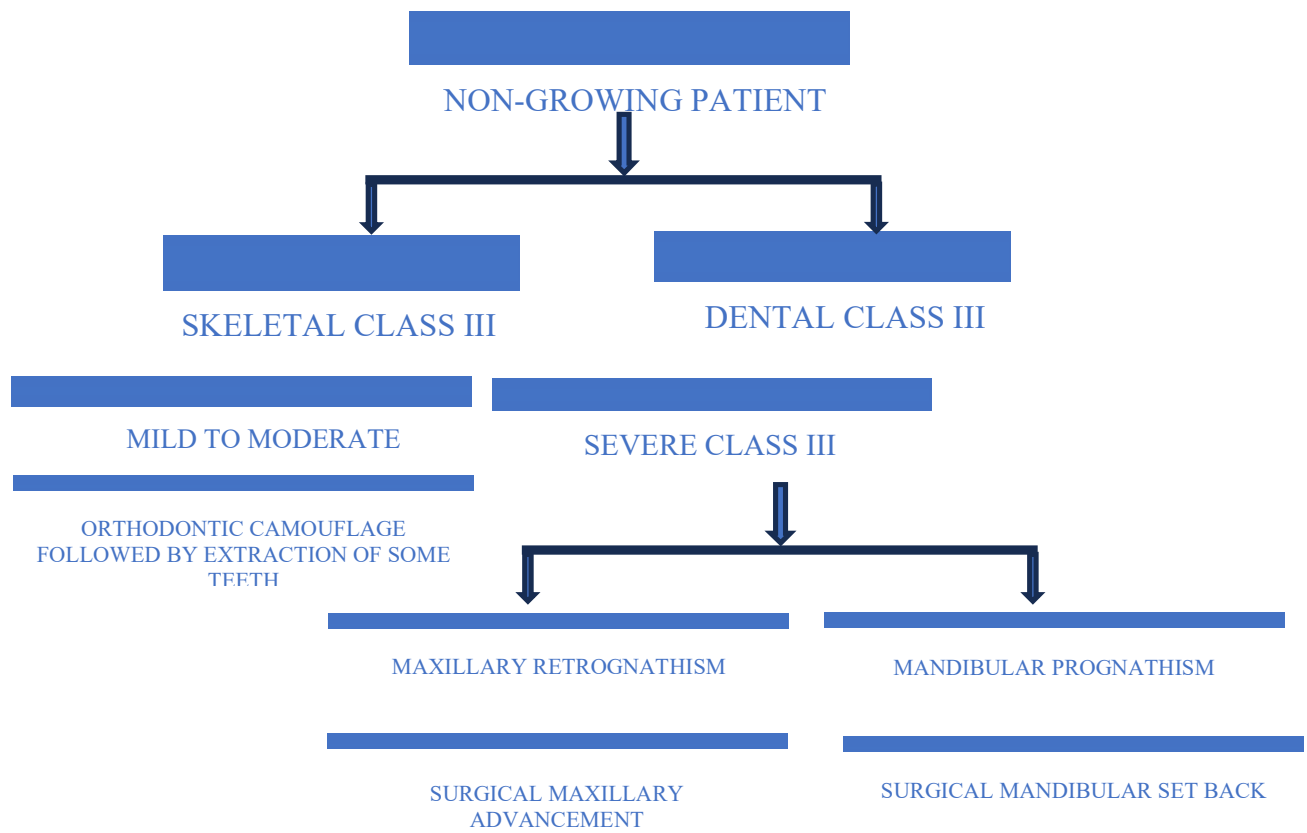
Genetic influenced by Environmental factors

Diagnosis



Treatment planning





Treatment planning

